

Acute encephalopathy associated with hemolytic uremic syndrome caused by *Escherichia coli* O157: H7 and rotavirus infection

G. IMATAKA¹, K. WAKE², M. SUZUKI³, H. YAMANOUCHI⁴, O. ARISAKA¹

¹Department of Pediatrics, Dokkyo Medical University School of Medicine, Tochigi, Japan

²Department of Emergency and Critical Care Medicine, Dokkyo Medical University School of Medicine, Tochigi, Japan

³Department of Pediatric Neurology, Aichi Children's Health and Medical Center, Aichi, Japan

⁴Department of Pediatrics, Saitama Medical University, Saitama, Japan

Abstract. – We reported a case of a 22-months child with hemolytic uremic syndrome associated with encephalopathy. As the cause of this case, the involvements of verotoxin 1 and 2 caused by O157: the H7 strain of the enterohemorrhagic *Escherichia coli* and rotavirus were presumed. We administered brain hypothermic therapy and steroid pulse therapy in the intensive care unit, but we were not able to save his life and the child died on the 6th day from the onset.

Key Words:

EHEC, VT, Hemolytic uremic syndrome (HUS), Brain hypothermic therapy, Steroid pulse therapy.

Introduction

Rotavirus, the primary cause of viral gastroenteritis, causes children to vomit and have white diarrhea. The basic treatment is rehydration and correcting the electrolyte imbalances. Rotavirus inflammation in children may rarely develop into rotavirus encephalopathy that is accompanied by seizures and acute encephalopathy¹.

However, enterohemorrhagic *Escherichia coli* (EHEC) may cause, in addition to high fever, acute stomach aches and blood feces, hemolytic uremic syndrome (HUS) or acute encephalopathy, and may become a serious condition² for the patient. As EHEC produces verotoxin (VT), it is called verotoxin-producing *Escherichia coli* (VTEC).

We had a child patient who developed rotavirus encephalopathy accompanied by HUS encephalopathy caused by O157: H7. As we have no record of such a case in the past, we report the progression of the case.

Care Report

The 22-month old male child was transported to our hospital as he was observed with high fever, vomiting, and status epilepticus. His family history and motor developments were normal. When he arrived at our hospital, he was in cardiopulmonary arrest, and the resuscitative maneuver was immediately conducted in the emergency room. His heartbeat resumed for at least 15 minutes, but no spontaneous breathing was observed. The diameters of the pupils of both eyes were 6 mm and fixed, the light reflex was lost. After the commencement of artificial respiration, he responded to pain stimulations with shaking off actions but did not open his eyes. Head CT revealed a diffuse edema in the brain (Figure 1). An enormous amount of water diarrhea was observed, and the result of the rapid antigen test for rotavirus was positive. Based on the clinical course, we diagnosed it as rotavirus related encephalopathy, and we hospitalized him in ICU and commenced the brain hypothermic therapy and the steroid pulse therapy. The result of the blood test was: WBC 14,000/ μ L, hemoglobin 6.0 g/dL, platelet 0.6×10^4 / μ L, BUN 36 mg/dL, Cre 1.8 mg/dL, AST 126 IU/L, CK 202 IU/L, CRP 0.3 mg/dl. Based on the progression, we diagnosed HUS concurrence, and we administered blood transfusion, anticoagulant therapy, and intracranial pressure reduction therapy simultaneously. As he developed disseminated intravascular coagulation (DIC) on the second day of intensive care, we stopped the brain hypothermic therapy after 24 hours. As we checked the electroencephalogram, it showed flat waves without the base activities (Figure 2). In the fecal bacterial cultivation upon admission, only resident bacteria were detected, but when we conducted

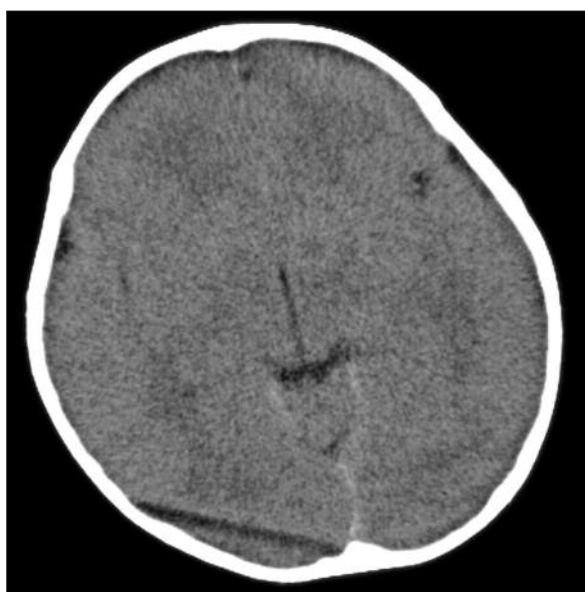


Figure 1. Cephalic CT on the first day on hospitalization. CT revealed severe form of diffuse cerebral edema.

O-157:7 direct method on the third day of HUS progression, it indicated positive. As we conducted the verotoxin (VT) quick test by enzyme immunoassay (EIA) method and immune chromatography method, VT1 and VT2 were positive in both tests. The child died on the sixth day of hospitalization. The infection route of O157: H7 was unknown.

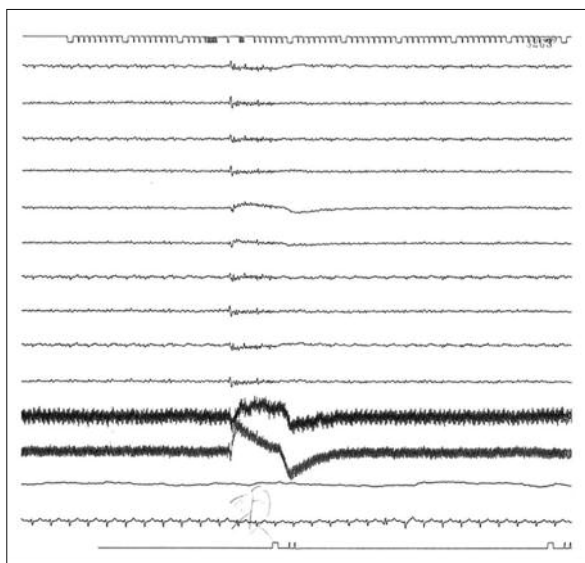


Figure 2. Electroencepharogram on the 2nd day from hospitalization. The patient's EEG exhibited low-voltage and flat background activity.

Discussion

The HUS can be diagnosed with hemolytic anemia, a decrease in platelets and acute disorder of the kidney. The HUS occurs 10% or less in EHEC. Central nervous system manifestations accompany EHEC-associated HUS, and 5% or less of the cases leads to death due to acute encephalopathy and perforation of the digestive tract³. CT/MRI⁴ and the brain waves⁵ are effective means to diagnose HUS encephalopathy. Mild cases of HUS encephalopathy cannot be detected by CT. However, serious cases present abnormalities in the splenium of the corpus callosum, and both sides of the optic thalamus and in the nucleus basalis⁶. The most serious cases are present edema in the brain and brain hernia⁶. On the other hand, the brain waves show abnormalities of base activities even in mild cases of HUS encephalopathy. Severe cases of HUS encephalopathy present high-amplitude slow wave⁵. In this particular case, we observed a severe degree of edema in the brain by CT scan upon the admission of the patient. As treatments of HUS encephalopathy, plasma exchange therapy⁷, dialysis, anticoagulant therapy⁸, pressure reduction therapy and other therapies are conducted, but there is no established treatment. We kept him under intensive care and administered brain hypothermic therapy⁹ and steroid pulse therapy¹⁰, but the child died on the sixth day of hospitalization.

There are two occurrence mechanisms for O157-triggered HUS encephalopathy. One occurs as Shiga Toxin of VT1 and VT2 disturbs protein synthesis on the vascular endothelial¹¹. The other occurs as TNF- α and IL-1 β are produced via lipopolysaccharide (LPS) and induce inflammatory cytokines such as IL-6 or IL-8 to destroy the renal vascular endothelial and the blood-brain barrier that allows Shiga toxin to affect the brain directly^{12,13}. Abnormalities of the electrolytes and the circulation balance caused by acute kidney disorder and the TNF can be exacerbating factors as well.

The VT1 and VT2 were found in our case as well. And the rotavirus antigens in the feces of the child were positive. Rotavirus is known to cause various central nervous system manifestations. In the case of rotavirus encephalopathy, the viruses may be found in the spinal fluid PCR, and clarification of the occurrence mechanism is much desired¹. It is unknown that how much rotavirus affected the HUS encephalopathy in our

case. However, in the entire body condition, it was much contributing to making dehydration and diarrhea serious, and we can assume that it was an exacerbating factor.

Conclusions

To our best of knowledge, the present case was the most severe form of HUS encephalopathy.

Conflict of Interest

The Authors declare that there are no conflicts of interest.

References

- 1) KASHIWAGI Y, KAWASHIMA H, SUZUKI S. Rotavirus encephalopathy. *Nihon Rinsho* 2011; 69: 429-434.
- 2) SHETH KJ, SWICK HM, HAWORTH N. Neurologic involvement in hemolytic-uremic syndrome. *Ann Neurol* 1986; 19: 90-93.
- 3) ROBSON WL, LEUNG AK, MONTGOMERY MD. Cause of death in hemolytic uremic syndrome. *Child Nephrol Urol* 1991; 11: 228-233.
- 4) STEINBORN M, LEIZ S, RUDISSLER K, GRIEBEL M, HARDER T, HAHN H. CT and MRI in hemolytic uremic syndrome with central nervous system involvement: distribution of lesions and prognostic value of imaging findings. *Pediatr Radiol* 2004; 34: 805-810.
- 5) DHUNA A, PASCUAL-LEONE A, TALWAR D, TORRES F. EEG and seizures in children with hemolytic-uremic syndrome. *Epilepsia* 1992; 33: 482-486.
- 6) DONNERSTAG F, DING X, PAPE L, BULTMANN E, LUCKE T, ZAJACZEK J, HOY L, DAS AM, LANFERMANN H, EHRICH J, HARTMANN H. Patterns in early diffusion-weighted MRI in children with haemolytic uremic syndrome and CNS involvement. *Eur Radiol* 2012; 22: 506-513.
- 7) DUNDAS S, MURPHY J, SOUTAR RL, JONES GA, HUTCHINSON SJ, TODD WT. Effectiveness of therapeutic plasma exchange in the 1996 Lanarkshire Escherichia coli O157:H7 outbreak. *Lancet* 1999; 354: 1327-1330.
- 8) O'REGAN S, CHESNEY RW, MONGEAU JG, ROBITALLE P. Aspirin and dipyridamole therapy in the hemolytic-uremic syndrome. *J Pediatr* 1980; 97: 473-476.
- 9) IMATAKA G, WAKE K, YAMANOUCHI H, ONO K, ARISAKA O. Brain hypothermic therapy for status epilepticus in childhood. *Eur Rev Med Pharmacol Sci* 2014; 18: 1883-1888.
- 10) PEREZ N, SPIZZIRRI F, RAHMAN R, SUAREZ A, LARRUBIA C, LASARTE P. Steroids in hemolytic uremic syndrome. *Pediatr Nephrol* 1998; 12: 101-104.
- 11) LAPEYRAQUE AL, MALINA M, FREMEAUX-BACCHI V, BOPPEL T, KIRSCHFINK M, OUALHA M, PROULX F, LE DEIST F, NIAUDET P, SCHAEFER F. Eculizumab in severe Shiga-toxin-associated HUS. *N Engl J Med* 2011; 364: 2561-2563.
- 12) SHIMIZU M, KURODA M, SAKASHITA N, KONISHI M, KANEIDA H, IGARASHI N, YAMAHANA J, TANEICHI H, KANEGANE H, ITO M, SAITO S, OHTA K, TANIGUCHI T, FURUUCHI K, WADA T, NAKAGAWA M, YOKOYAMA H, YACHIE A. Cytokine profiles of patients with enterohemorrhagic Escherichia coli O111-induced hemolytic-uremic syndrome. *Cytokine* 2012; 60: 694-700.
- 13) SHIRAISHI M, ICHIYAMA T, MATSUSHIGE T, IWAKI T, IYODA K, FUKUDA K, MAKATA H, MATSUBARA T, FURUKAWA S. Soluble tumor necrosis factor receptor 1 and tissue inhibitor of metalloproteinase-1 in hemolytic uremic syndrome with encephalopathy. *J Neuroimmunol* 2008; 196: 147-152.