



A Case Report of Non-Herpetic Limbic Encephalitis with Psychological Symptoms and Parkinsonism

**George IMATAKA, Shigemi YOSHIHARA*

Department of Pediatrics, Dokkyo Medical University, Tochigi, Japan

***Corresponding Author:** Email: geo@dokkyomed.ac.jp

(Received 05 Apr 2020; accepted 19 Apr 2020)

Dear Editor-in-Chief

Simple herpetic and non-herpetic limbic encephalitis (NHLE) are known causes of limbic encephalitis. The age of onset of NHLE is higher among young women (1). Moreover, NHLE is associated with the development of malformative teratomas in the abdominal cavity. The clinical course is varied with symptoms such as hallucinations, visual delusions, and dementia-like symptoms (1).

Here, we report a case of a young female patient with NHLE without teratoma who developed parkinsonism with psychiatric symptoms as the initial symptoms of her clinical course.

A 14-yr-old girl was hospitalized due to involuntary movements of her left arm and emotional instability and informed consent was obtained from parents. She had no prior disease history when we first showed signs of emotional instability and developed low-grade fever for a month

before hospitalization. She abused her parents 3 days before admission, and had fever and short-term impairment of consciousness in the time of admission. During the routine physical examination, she showed noticeable sweating, especially on her hands. A few days later, she developed a fever and was unable to sleep during the night. Her memory disorder got worse and conversation with her became problematic. She also developed a resting tremor in both hands. In addition, her movements became sluggish and she was unable to walk normally. Her limbs were stiff and she suffered from severe constipation.

We diagnosed her clinical condition as Parkinsonism. Her handwriting was small and she could write a continuous line using small letters. When she was asked to draw, she could only generate small drawings (Fig. 1).

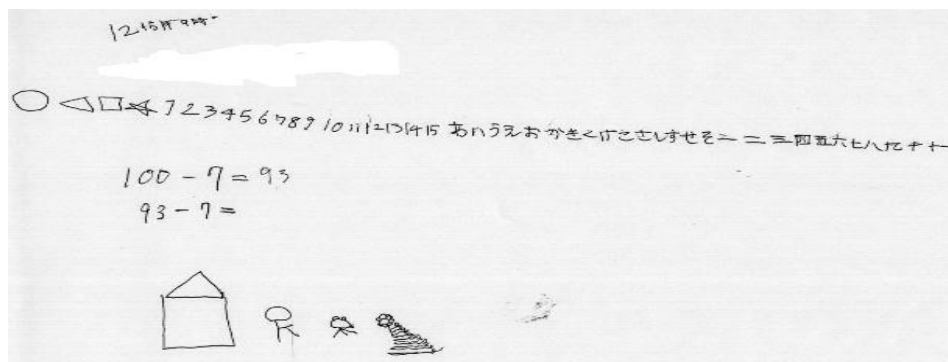


Fig. 1: Patient's writing and drawing on the 4th day of admission.

Results from her blood test on the 3rd day after her admission revealed WBC count of 1,400/ μ l, CRP level of 0.68 mg/dl, and CK level of 872 U/l. Cerebrospinal fluid (CSF) examination showed a cell count of 4/ μ l, protein level of 15 mg/dl, and glucose level of 59 mg/dl. CSF neopterin level was 33.35 pmol/ml; biopterin level was 11.21 pmol/ml; and the N/B ratio was 2.97. Anti-NMDA receptor antibody and Anti-GluR receptors were tested negative. PCR tests for CSF herpes simplex virus were negative. Brain MRI revealed no abnormalities and EEG results exhibited no epileptic discharges. Her abdominal echogram was normal with no evidence of teratoma. On the 5th, brain 18F-fludeoxyglucose positron emission tomography (18F-FDG-PET) revealed an increase in hyper perfusion, predominantly in the right lenticular nucleus (Fig. 2A/B). Based on her clinical course we diagnosed NHLE and we prescribed methylprednisolone at 1,000 mg/day for 3 days as steroid pulse therapy. After the therapy, her consciousness level improved over time. After a month, her Parkinsonism had almost disappeared and the lenticular nuclear hyper perfusion had improved (Fig. 2C/D). She was discharged without sequelae 2 months after admission.

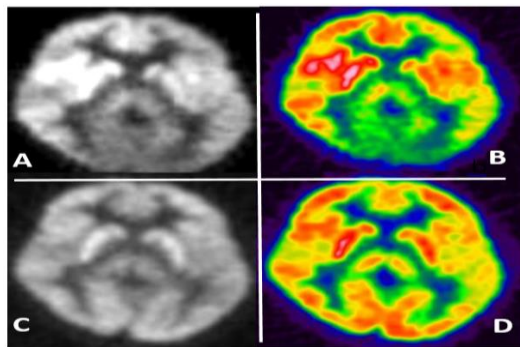


Fig. 2: Brain 18F-FDG PET on days 5 (A/B) and 30 (C/D)

Parkinsonism is characterized by symptoms of Parkinson's disease, which can arise from different causes other than the classic disease. Parkinsonism is known to occur due to manganese poi-

soning, drug side effects, degenerative diseases of the basal ganglia, and viral and post-viral infectious encephalitis (2). Parkinsonism associated with NHLE has been rarely reported (3). Our case developed limbic encephalitis, possibly following some non-herpetic viral infection. Parkinsonism in this case appeared when brain FDG-PET revealed abnormalities in the lenticular nucleus of the basal ganglia. After steroid pulse treatment, her symptoms as well as findings of FDG-PET improved. Brain FDG-PET reflects the metabolic capacity of glucose in the cerebrum. FDG-PET was useful for monitoring the mechanism of parkinsonism in this case. Only a few studies have discussed FDG-PET as a useful tool for the early detection of NHLE (4). Even though NHLE is a very rare disease, steroid pulse therapy may be an effective treatment in patients with parkinsonism and brain FDG-PET investigations may be valuable for assessing its course.

Conflict of interest

The authors declare that there is no conflict of interest.

References

1. Fujiki Y, Tsuboi K, Hashimoto, et al (2004). Non-herpetic Limbic Encephalitis Associated With Relapsing Polychondritis. *J Neurol Neurosurg Psychiatry*, 75 (11):1646-7.
2. Tomás R Guilarte, Kalynda K Gonzales (2015). Manganese-Induced Parkinsonism Is Not Idiopathic Parkinson's Disease: Environmental and Genetic Evidence. *Toxicol Sci*, 146 (2): 204-12.
3. Matsuzono K, Kurata T, Deguchi S, et al (2013). Two unique cases with anti-gluR antibody-positive encephalitis. *Clin Med Insights Case Rep*, 6: 113-7.
4. Cózar PS, Sanchez RJ, Sanz RL, Aguilar JB, Ferrer JR (2016). Limbic encephalitis diagnosed with 18F-FDG PET/CT. *Clin Nucl Med*, 41 (2): e101-3.