

Immature ovarian teratoma with anti-NMDA-receptor encephalitis in a 13-year-old Japanese female patient

George Imataka, MD, Shigemi Yoshihara, MD

Department of Paediatrics, Dokkyo Medical University, Tochigi, Japan

SUMMARY

We report a 13-year-old Japanese female with ovarian teratoma due to anti-NMDAR encephalitis. The patient was admitted with psychiatric symptoms, including memory impairment, insomnia, binge eating and mouth and hand twisting, associated with constipation. Serum alpha-fetoprotein and neopterin levels were elevated 102 ng/mL and 19 pmol/mL, respectively. Electroencephalography showed epileptic spikes in frontal and temporal regions. Cerebrospinal fluid (CSF) examination exhibited a pleocytosis. Thereafter, her consciousness level immediately worsened. Brain magnetic resonance imaging (MRI) noted hyper intense lesions in bilateral hippocampi, she was diagnosed with limbic encephalitis. Abdominal echogram showed a solid right ovarian tumour, and also confirmed as a tumour by abdominal MRI. The next day, right ovariectomy was performed and she treated two courses of methyl-prednisolone steroid pulse with high-dose immunoglobulins. Later days, CSF analysis revealed anti-NMDAR antibodies. Pathological diagnosis of the tumour was immature round shaped grade 3 ovarian teratoma, measuring 11cm. Two years follow up after admission, she completely recovered and no neurological sequelae.

INTRODUCTION

Anti-N-methyl-D-Aspartate receptor (NMDAR) encephalitis is rare form of autoimmune encephalitis. In addition, abdominal ovarian tumour complications have been reported. We read with interest the report by Mahendra et al.¹ of a 16-year-old female with ovarian teratoma associated with anti-N-methyl-D-Aspartate receptor (NMDAR) encephalitis diagnosed with rectal sonography and histological examination of the cystic mass. We also treated a similar case of a 13-year-old Japanese female patient with ovarian teratoma associated with anti-NMDAR encephalitis.

CASE REPORT

Two weeks after a bout of common cold, the above patient was hospitalized with psychiatric symptoms, including memory impairment, insomnia, binge eating and twisting of mouth and hand, and accompanied with constipation. Differential diagnosis included schizophrenia, epilepsy, depression and encephalitis. Blood and urine tests were normal. She was negative for antinuclear, anti-double-stranded DNA and anti SS-A antibodies. Alpha-fetoprotein and neopterin levels were 102 ng/mL and 19 pmol/mL,

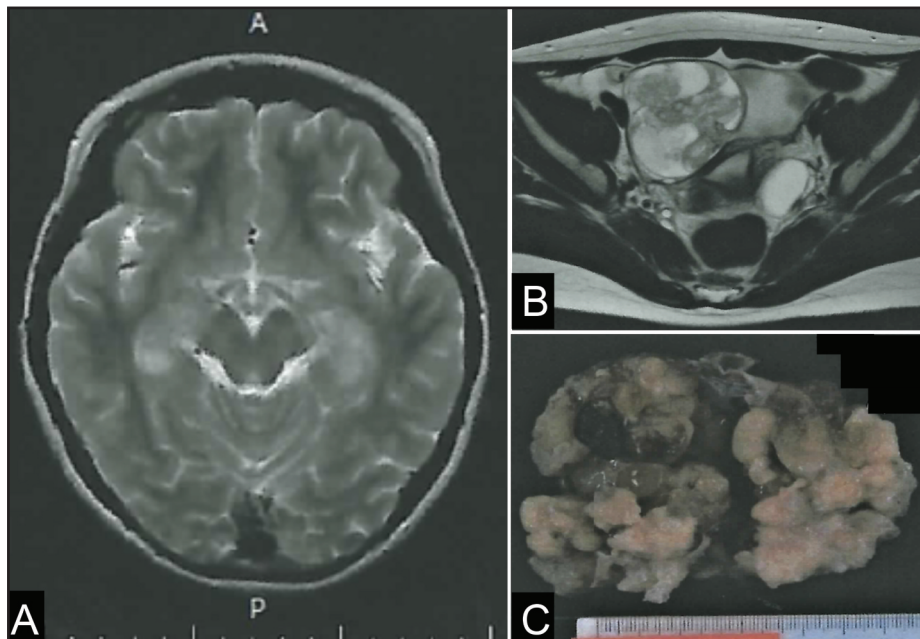


Fig. 1: (A) Magnetic resonance fluid-attenuated inversion-recovery image at admission showing hyper intense lesions in bilateral hippocampi. (B) Abdominal magnetic resonance image showing a round tumour, 11 cm in size, with a non-uniform signal. (C) The maximum diameter of the mass is 12.0 cm.

This article was accepted: 28 March 2021

Corresponding Author: George Imataka

Email: geo@dokkyomed.ac.jp

respectively. Brain computed tomography findings were normal. Electroencephalography revealed sporadic spikes in frontal and temporal regions. Cerebrospinal fluid (CSF) analysis revealed a pleocytosis. The tentative diagnosis was viral encephalitis, and acyclovir and cefotaxime were initiated. However, her consciousness worsened immediately and her brain magnetic resonance imaging (MRI) revealed hyper intense lesions in bilateral hippocampi (Fig. 1A). She was diagnosed with limbic encephalitis, and abdominal ultrasonography revealed a solid right ovarian mass, which was diagnosed as a tumour by abdominal MRI (Fig. 1B). The updated diagnosis was anti-NMDA encephalitis due to an ovarian tumour, and right ovariectomy was performed the next day (Fig. 1C). After the operation, she received two courses of methyl-prednisolone steroid pulse (30 mg/kg, 3days) and high-dose immunoglobulins (400 mg/kg/5 days). One week after operation, she was apathetic during the day and apnoeic at night and had lost >10% body weight. She was administered valproic acid for repeated generalized seizures. Moreover, serum and CSF examination at admission revealed the presence of anti-NMDAR antibodies. She received another course of steroid pulse therapy, with subsequent, gradual improvements in mental state and memory. She was discharged two months after initial admission. The pathological diagnosis of the right ovarian tumour was immature grade 3 teratoma. Her IQ was 97 on evaluation two years after surgery, and antiepileptic drug treatment was discontinued at that time.

DISCUSSION

In a study of limbic encephalitis by Dalmau et al.,² 91 of the 100 patients were females; young female patients were predominant and 62% of the female patients had tumours, most of which were ovarian teratomas. Early tumour removal and immunotherapy are important for favourable outcomes in limbic encephalitis.³ A microscopic teratoma was detected on autopsy in a case report. Therefore, exploratory laparotomy should be considered in severe refractory cases.⁴ The prognosis was good following tumour excision in our case, similar to that reported by Mahendra et al.¹ Sudden appearance of psychiatric symptoms in young female patients should warrant prompt brain MRI and abdominal examination for potential ovarian teratoma associated with anti-NMDA-receptor encephalitis.

REFERENCES

1. Mahendra INB, Saspriyana KY, Ekawati NP. Mature ovarian teratoma associated with anti-N-Methyl-D-aspartate receptor encephalitis: A case report. *Med J Malaysia*. 2021 Jan;76(1):110-113.
2. Dalmau J, Gleichman AJ, Hughes EG, Rossi JE, Peng X, Lai M, et al: Anti-NMDA-receptor encephalitis: case series and analysis of the effects of antibodies. *Lancet Neurol* 2008; 7(12): 1091-8.
3. Dai Y, Zhang J, Ren H, Zhou X, Chen J, Cui L, et al.. Surgical outcomes in patients with anti-N-methyl D-aspartate receptor encephalitis with ovarian teratoma. *Am J Obstet Gynecol* 2019; 221(5): 485.e1-10.
4. Iizuka T, Sakai F, Mochizuki H. Update on anti-NMDA receptor encephalitis. *Brain Nerve* 2010; 62(4): 331-8.