

Advance Publication by J-STAGE
Clinical Pediatric Endocrinology

Accepted for publication: March 6, 2024

Advanced Epub: March 25, 2024

Case Report

Pseudohypoparathyroidism type 1B with involuntary movements: a case report and literature review

Junko Naganuma¹, Hiroshi Suzumura¹, Satomi Koyama¹, Miho Yaginuma¹, Yuji Fujita¹, Yoshiyuki Watabe¹, George Imataka¹, Keiko Matsubara^{2,3}, Masayo Kagami², and Shigemi Yoshihara¹

¹Department of Pediatrics, Dokkyo Medical University, Tochigi 321-0293, Japan

²Department of Molecular Endocrinology, National Center for Child Health and Development, Tokyo 157-8535, Japan

³Division of Diversity Research, National Research Institute for Child Health and Development, Tokyo 157-8535, Japan

Running head: PHP 1B with involuntary movements

Corresponding authors: Junko Naganuma, M.D., Ph.D., Department of Pediatrics Dokkyo Medical University, 880 Kitakobayashi, Mibu Shimotsuga, Tochigi 321-0293, Japan E-mail: junko@dokkyomed.ac.jp; Masayo Kagami, M.D., Ph.D., Department of Molecular Endocrinology, National Center for Child Health and Development, 2-10-1 Okura, Setagaya-ku, Tokyo 157-8535, Japan. E-mail: kagami-ms@ncchd.go.jp

Highlights

- PHP is characterized by hypocalcemia and hyperparathyroidism due to PTH resistance.
- PHP is rare and unlikely to be accompanied by involuntary movements.
- Patients experiencing exercise-induced involuntary movements may have PHP.

Abstract

Pseudohypoparathyroidism (PHP) is a rare disorder characterized by convulsions, tetany, and sensory abnormalities caused by hypocalcemia due to parathyroid hormone (PTH) resistance. Only few patients present with involuntary movements. We report the case of a 7-yr-old girl with PHP and involuntary movements triggered by running. Initially, she was suspected of having paroxysmal kinesigenic dyskinesia and was treated with carbamazepine (CBZ). Involuntary movements were reduced. However, 2 months post-treatment, she experienced convulsions during a fever. Blood tests and brain computed tomography revealed hypocalcemia, hyperphosphatemia, elevated intact PTH, and calcifications in the frontal cortex and basal ganglia. The patient showed no features of Albright's hereditary osteodystrophy. The involuntary movements disappeared after the discontinuation of CBZ and initiation of calcium and active vitamin D preparations. Methylation-specific multiplex ligation-dependent probe amplification for the *GNAS* region and microsatellite analysis of chromosome 20 led to the diagnosis of PHP1B caused by epimutation. In 15 reported cases, with or without intracranial calcification, PHP-associated involuntary movements disappeared or became less severe with treatment for hypocalcemia; in eight of 11 cases, they were triggered by exercise or movement. PHP-associated hypocalcemia can trigger exercise-induced involuntary movements owing to lowered serum ionized calcium levels. In such patients, early blood tests are vital for the differential diagnosis of PHP.

Key words: involuntary movement, pseudohypoparathyroidism 1B, hypocalcemia

Introduction

Pseudohypoparathyroidism (PHP) is a genetically heterogeneous condition characterized by hypocalcemia and hyperphosphatemia resulting from end-organ resistance to parathyroid hormone (PTH) (1, 2). However, its exact prevalence remains unknown. Previous studies have estimated the prevalence to be 1.2 per 100,000 in Japan (3) and 1.1 per 100,000 in Denmark (4).

There are two forms of PHP, PHP1 and PHP2 (5). PHP1 is further sub-divided into PHP1A and PHP1B. PHP1A arises from loss-of-function variants that affect maternal *GNAS* exons 1–13, which encode the stimulatory G protein α -subunit (1, 2). PHP1B is caused by methylation abnormalities in differentially methylated regions (DMRs) upstream of the *GNAS* gene (1, 2) and can follow an autosomal dominant mode of inheritance or occur sporadically (1, 2). Sporadic-PHP1B presents with broad methylation changes in two or more DMRs, and its etiology includes paternal uniparental disomy of chromosome 20 and epimutation (1). PHP1B is less likely to be accompanied by symptoms of Albright's hereditary osteodystrophy (AHO) (1), and early diagnosis is difficult in the absence of generalized convulsions, tetany, and sensory abnormalities associated with hypocalcemia (1). Only a few case reports of involuntary movements have been published. We present the case of a patient with PHP1B-associated involuntary movements and discuss its pathology.

Patient and Methods

The 7-yr-old female patient was born at 39 wk and 3 d of gestation, with a birth weight of 3,060 g (+0.2 standard deviation [SD]) and a height of 51 cm (+1.2 SD). Her developmental milestones were unremarkable; however, she had a history of febrile seizures at 1 yr of age. The patient had no family history of endocrine disorders or epilepsy. At the age of 7 yr and 2 mo, the patient showed involuntary movements triggered by running, raising her left hand, dropping her right hand behind her, and flexing both wrists. At 7 yr and 4 mo, the involuntary movements of the upper extremities increased from once every few days to several times a day, and the lower extremities began to jerk when she

began walking, although she did not present with consciousness-related symptoms. She visited the pediatric neurology outpatient clinic, where an interictal electroencephalogram showed no abnormalities, but no blood or brain imaging was conducted. Carbamazepine (CBZ) was initiated on the suspicion of paroxysmal kinesigenic dyskinesia (PKD) based on her clinical symptoms and interictal electroencephalogram results; subsequently, the dyskinesia disappeared.

Two months after CBZ treatment initiation, the patient was transferred to our hospital with fever and convulsions. She was 114 cm tall (−1.4 SD), weighed 19.8 kg (−0.8 SD), had a body mass index of 15 kg/m², and had no clinical features related to AHO. Her vital signs were as follows: temperature, 38.6°C; blood pressure, 109/73 mmHg; heart rate, 127 beats/min; and SpO₂, 96% (room air). The generalized tonic convulsions lasted for 3 min, and her level of consciousness was normal when she arrived at the hospital. Blood tests revealed no hyponatremia, hypoglycemia, or renal dysfunction. Serum levels [normal range] of calcium (Ca), phosphorus (P), intact PTH, 1,25-dihydroxyvitamin D₃, and 25-hydroxyvitamin D were 5.5 [8.7–10.2] mg/dL, 7.6 [3.9–5.8] mg/dL, 343.1 [10–65] pg/mL, 74.3 [20–60] pg/mL, and 13.5 [> 20] ng/mL, respectively. Thyroid function was normal (thyroid stimulating hormone: 0.881 [0.8–6.0] μ IU/mL; free thyroxine: 1.0 [1.0–2.1] ng/dL; free triiodothyronine: 3.22 [2.73–4.69] pg/mL). Computed tomography (CT) of the brain revealed multiple bilateral calcifications in the basal ganglia (BG) and frontal cortex (Fig. 1). Ophthalmological examination revealed pale opacities and bulging of the lens, indicating cataract. Electrocardiography revealed QT prolongation, with a QTc of 0.496 [0.35–0.43] msec. The patient was admitted to the hospital for a closer examination and to treat the hypocalcemia. The oral administration of CBZ was discontinued after hospitalization. Calcium gluconate was administered intravenously seven times for hypocalcemia, and serum Ca levels were maintained above 7.0 mg/dL from day 5 after treatment initiation. Furthermore, QT prolongation on electrocardiography improved with the correction of serum Ca levels. After her general condition improved, the Ellsworth-Howard test was performed to examine the cause of the hypocalcemia. The urinary phosphate response to PTH administration was 5 mg/2 h (positive at > 35 mg/2 h), and the urinary cyclic AMP response was 0.99 μ mol/1 h (positive at > 1 μ mol/1 h), both indicating a lack of an increased excretory response to PTH

and thus a diagnosis of PHP type 1. The patient's condition stabilized and she was discharged on the 23rd day after admission. Oral administration of an active vitamin D preparation (alfacalcidol 1 µg/d) was started on the 31st day of illness. Serum Ca levels remained consistently within 8–9 mg/dL, P levels were stable at approximately 5 mg/dL, and intact PTH levels remained within 200–300 pg/mL. After treatment initiation, the patient did not experience any symptoms of dyskinesia in the upper or lower extremities.

For molecular analysis of the *GNAS* region, we employed methylation-specific multiplex ligation-dependent probe amplification (MS-MLPA) using SALSA ME031 probe mix (MRC-Holland, Amsterdam, Netherlands). MS-MLPA revealed abnormal methylation patterns in *GNAS*-DMRs, such as hypermethylation of *NESP55*-DMR and hypomethylation of *GNAS-AS*, *-XL*, and *-A/B*-DMR, without copy number changes (Fig. 2). Microsatellite analysis of chromosome 20 using samples from the patient and her parents showed a biparental origin of the chromosome; therefore, paternal uniparental disomy of chromosome 20 was ruled out. Sequence analysis revealed no mutation of the *GNAS* gene (data not shown). We conclude that the etiology of sporadic PHP1B is epimutation.

Statement of ethics

Written informed consent was obtained from the parent/legal guardian of the patient for the publication of the details of their medical case and any accompanying images in accordance with the Declaration of Helsinki.

Discussion

We reported the case of a 7-yr-old girl presenting with involuntary movements of lifting her upper limbs triggered by running. She was initially suspected to have PKD and was treated with CBZ. After convulsions during a high fever, she was diagnosed with PHP1B based on the results of blood tests

and molecular analyses. The involuntary movements disappeared after normalization of Ca levels following the administration of Ca and active vitamin D preparations.

Only a few cases of PHP-associated involuntary movements have been reported (Table 1) (6–17). Our patient was initially suspected of having PKD because her symptoms met the clinical diagnostic criteria for PKD, such as seizures triggered by motor movements, no pain or loss of consciousness during the seizure, age of onset under 20 years, no other organic diseases, normal neurological examination during seizures, and effectiveness of CBZ (18, 19). She was diagnosed with PHP1B based on blood tests and molecular analysis following convulsions during a high fever. Considering that the diagnostic criteria for PKD include the exclusion of other organic diseases (18, 19), it was not a suitable diagnosis.

The patient did not undergo blood tests when CBZ treatment was initiated for involuntary movements. Considering the patient's clinical course, we speculated that she had hypocalcemia at the onset of the involuntary movements. Furthermore, the involuntary movements disappeared after initiating treatment for hypocalcemia, despite the discontinuation of CBZ. To the best of our knowledge, only 15 patients with PHP-related involuntary movements have been reported (Table 1) (6–17). In all cases, with or without intracranial calcification, the involuntary movements disappeared or became less severe with hypocalcemia treatment. These findings suggest that the involuntary movements were caused by hypocalcemia. In eight of the previously reported 11 patients with PHP-associated involuntary movements and intracranial calcification, the involuntary movements were triggered by exercise or movement, similar to the current case (7, 8, 10, 11, 12, 14, 15). Additionally, Parkinsonism was observed in three cases of adult PHP (13, 16, 17). Early blood tests to detect hypocalcemia in patients with exercise-induced involuntary movements should be considered in the differential diagnosis of PHP. Furthermore, for adult patients with parkinsonism, blood tests to detect hypocalcemia may be needed for the differential diagnosis of PHP.

The mechanism underlying hypocalcemia-induced involuntary movements remains unclear. Voluntary movements are regulated through the cerebral cortex- BG-thalamus loop with the coordination of excitatory and inhibitory neurons (20). In inhibitory neurons, Ca influx into the

presynaptic terminus releases synaptic vesicles containing gamma-aminobutyric acid (GABA), a crucial inhibitory neurotransmitter transmitted to the postsynaptic membrane (21). Hypocalcemia may suppress the functions of GABAergic inhibitory neurons, cause excitatory neurons to become dominant, and trigger involuntary movements. In a previous study, cases of PHP with involuntary movements together with hypocalcemia showed significant hypometabolism in the ventral putamen and inferior caudate on [18F]- fluorodeoxyglucose-positron emission tomography, altered BG metabolism, and resolution of clinical symptoms following Ca/calcitriol treatment (22). Furthermore, exercise can decrease serum ionized Ca levels (23), and decreased ionized Ca levels may further suppress the function of GABAergic inhibitory neurons and cause involuntary movements in patients with PHP-related hypocalcemia. Not all patients with PHP-associated hypocalcemia experience exercise-induced involuntary movements. Individual differences may exist in the susceptibility of GABAergic inhibitory neurons to hypocalcemia. CBZ was temporarily effective for the involuntary movements in our patient. CBZ suppresses glutamatergic excitatory projections and partially decreases involuntary movements (24). However, the association between brain calcification and involuntary movements remains unclear. Damage due to calcification in the cerebral cortex-BG-thalamus pathway can lead to involuntary movements; however, some patients do not show intracranial calcification (9, 13). Intracranial calcifications in the patient in the present case did not change after Ca levels normalized; nonetheless, involuntary movements were not observed. These findings suggest that the involuntary movements were caused by hypocalcemia rather than intracranial calcification.

Conclusion

This study showed that exercise-induced involuntary movements associated with PHP can be caused by hypocalcemia, with or without intracranial calcification. Based on this study and literature review, early blood tests to detect hypocalcemia in patients experiencing exercise-induced involuntary movements should be considered in the differential diagnosis of PHP.

Conflicts of interests: The authors have no conflicts of interest to declare.

Data availability statement: All data generated or analyzed during this study are included in this article. Further inquiries can be directed to the corresponding authors.

Acknowledgements

This work was supported by grants from the National Center for Child Health and Development (2022B-5) and the Japan Agency for Medical Research and Development (AMED) (23ek0109587h0002).

References

1. Mantovani G, Bastepe M, Monk D, de Sanctis L, Thiele S, Usardi A, *et al.* Diagnosis and management of pseudohypoparathyroidism and related disorders: first international Consensus Statement. *Nat Rev Endocrinol* 2018;14:476-500.
2. Eggermann T, Monk D, de Nancrales GP, Kagami M, Giabicani E, Riccio A, *et al.* Imprinting disorders. *Nat Rev Dis Primers* 2023;9:33.
3. Takatani R, Kubota T, Minagawa M, Inoue D, Fukumoto S, Ozono K, *et al.* Prevalence of pseudohypoparathyroidism and nonsurgical hypoparathyroidism in Japan in 2017: A nationwide survey. *J Epidemiol* 2023;33:569-73.
4. Underbjerg L, Sikjaer T, Mosekilde L, Rejnmark L. Pseudohypoparathyroidism – epidemiology, mortality and risk of complications. *Clin Endocrinol (Oxf)* 2016;84:904–11.
5. Drezner M, Neelon FA, Lebovitz HE. Pseudohypoparathyroidism type II: a possible defect in the reception of the cyclic AMP signal. *N Engl J Med* 1973;289:1056–60.
6. Visconti P, Posar A, Scaduto MC, Russo A, Tamburrino F, Mazzanti L. Neuropsychiatric phenotype in a child with pseudohypoparathyroidism. *J Pediatr Neurosci* 2016;11:267–70.
7. Thomas KP, Muthugovindan D, Singer HS. Paroxysmal kinesigenic dyskinesias and pseudohypoparathyroidism type Ib. *Pediatr Neurol* 2010;43:61–4.
8. Siejka SJ, Knezevic WV, Pullan PT. Aust N Z. Dystonia and intracerebral calcification: pseudohypoparathyroidism presenting in an eleven-year-old girl. *J Med* 1988;18:607-9.
9. Mahmud FH, Linglart A, Bastepe M, Jüppner H, Lteif AN. Molecular diagnosis of pseudohypoparathyroidism type Ib in a family with presumed paroxysmal dyskinesia. *Pediatrics* 2005;115:e242–4.

10. Zhang C, Zhou X, Feng M, Yue W. Paroxysmal dyskinesia and epilepsy in pseudohypoparathyroidism. *Mol Genet Genomic Med* 2020;8:e1423.
11. Garcia C, Correia CR, Lopes L. Pseudohypoparathyroidism type 1B - a rare cause of tetany: case report. *Paediatr Int Child Health* 2018;38:281–4.
12. Dure LS 4th, Mussell HG. Paroxysmal dyskinesia in a patient with pseudohypoparathyroidism. *Mov Disord* 1998;13:746–8.
13. Evans BK, Donley DK. J Neurol Pseudohypoparathyroidism, parkinsonism syndrome, with no basal ganglia calcification. *Neurosurg Psychiatry* 1988;51:709-13.
14. Kwon YJ, Jung JM, Choi JY, Kwon DY. Paroxysmal kinesigenic dyskinesia in pseudohypoparathyroidism: Is basal ganglia calcification a necessary finding? *J Neurol Sci* 2015;357:302-3.
15. Huang CW, Chen YC, Tsai JJ. Paroxysmal dyskinesia with secondary generalization of tonic-clonic seizures in pseudohypoparathyroidism. *Epilepsia* 2005;46:164-5.
16. Song CY, Zhao ZX, Li W, Sun CC, Liu YM. Pseudohypoparathyroidism with basal ganglia calcification: A case report of rare cause of reversible parkinsonism. *Medicine (Baltimore)* 2017;96:e6312.
17. Pearson DW, Durward WF, Fogelman I, Boyle IT, Beastall G. Pseudohypoparathyroidism presenting as severe Parkinsonism. *Postgrad Med J* 1981;57:445-7.
18. van Rootselaar AF, Schade van Westrum S, Velis DN, Tijssen MA. The paroxysmal dyskinesias. *Pract Neurol* 2009;9:102-9.
19. Bruno MK, Hallett M, Gwinn-Hardy K, Sorensen B, Considine E, Tucker S, *et al.* Clinical evaluation of idiopathic paroxysmal kinesigenic dyskinesia: new diagnostic criteria. *Neurology* 2004;63:2280-7.

20. Nambu A, Tokuno H, Takada M. Functional significance of the cortico-subthalamo-pallidal 'hyperdirect' pathway. *Neurosci Res* 2002;43(2):111–7.
21. Collin T, Marty A, Llano I. Presynaptic calcium stores and synaptic transmission. *Curr Opin Neurobiol* 2005;15:275–81.
22. Volonté MA, Perani D, Lanzi R, Poggi A, Anchisi D, Balini A, *et al.* Regression of ventral striatum hypometabolism after calcium/calcitriol therapy in paroxysmal kinesigenic choreoathetosis due to idiopathic primary hypoparathyroidism. *J Neurol Neurosurg Psychiatry* 2001;71:691-5.
23. Kohrt WM, Wherry SJ, Wolfe P, Sherk VD, Wellington T, Swanson CM, *et al.* Maintenance of Serum Ionized Calcium During Exercise Attenuates Parathyroid Hormone and Bone Resorption Responses. *J Bone Miner Res* 2018;33:1326–34.
24. Yang YC, Kuo CC. An inactivation stabilizer of the Na⁺ channel acts as an opportunistic pore blocker modulated by external Na⁺. *J Gen Physiol* 2005;125:465–81.

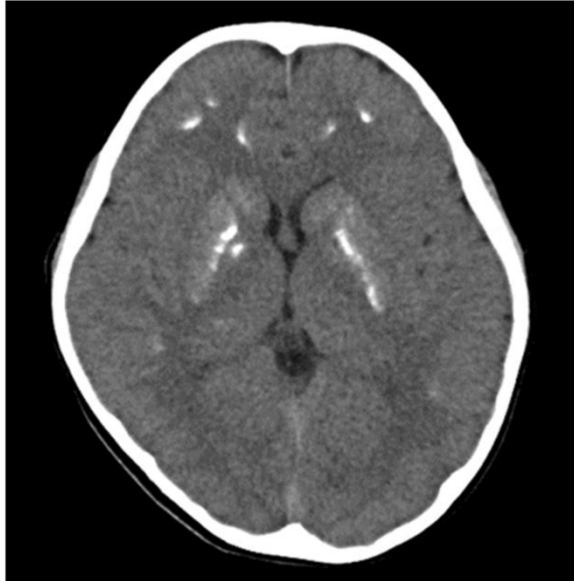


Fig. 1. Computed tomography scan of the head showing multiple calcifications in the basal ganglia and the frontal cortex.

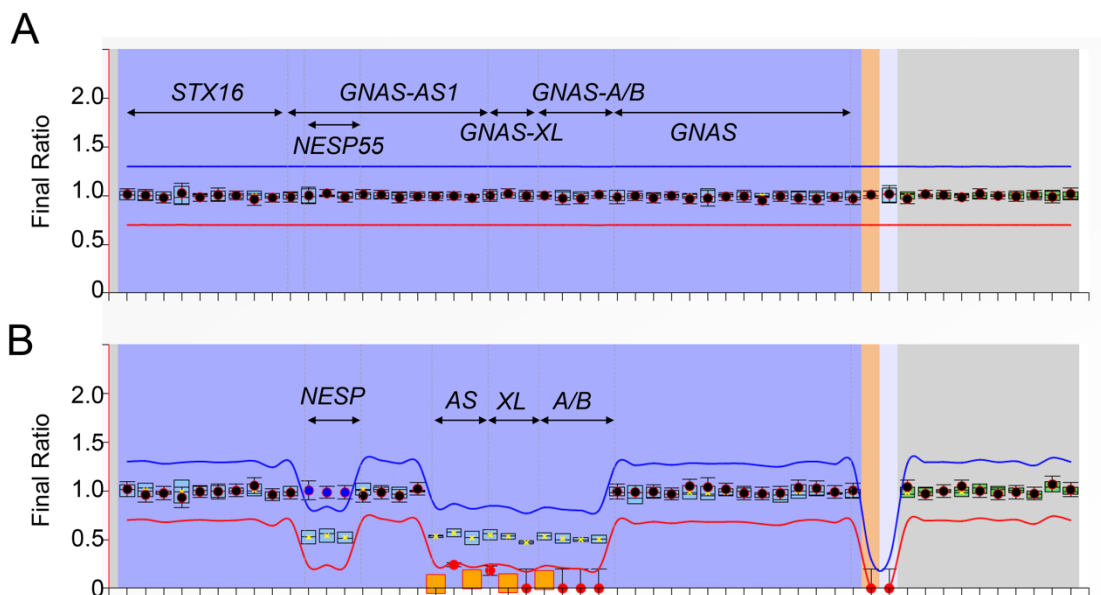


Fig. 2. Methylation-specific multiplex ligation-dependent probe amplification.

A: Copy number analysis. No copy number variants were detected within the pseudohypoparathyroidism - related regions.

B: Methylation analysis. Calculated ratios are reported on the y-axis and probes on the x-axis. The analysis revealed hypermethylation of the *NESP55* DMR and hypomethylation of *GNAS-AS*, *-XL*, and *-A/B* DMRs. DMR, differentially methylated region; TSS, transcription start site; *NESP*, *GNAS-NESP*:TSS-DMR; *AS*, *GNAS-AS1*:TSS-DMR; *XL*, *GNAS-XL*:Ex1-DMR; *A/B*, *GNAS A/B*:TSS-DMR.

Table 1. Reported PHP cases with involuntary movements

Age (yr)	Sex	Diagnosis	Involuntary movements	Trigger	Serum Ca level (mg/dL)	Neuroradiological imaging	Genetic analysis results	Treatment		Ref.
								Pre-Dx	Post- Dx	
7	F	Sporadic PHP1B	Raising the upper limbs	Running	5.5	CT: calcification in BG MRI: high signal coincident with calcified area in T2	Hypermethylation of <i>NESP55</i> DMR and hypomethylation of <i>GNAS</i> -AS, -XL, -A/B DMR	CBZ	Ca and Vit D	This case
9	M	Sporadic PHP1B	Ocular motor tics, throat tightness, and eye mutation	—	6.7	CT: calcification in bilateral subcortical, lens nuclei, and thalamus	Multiple changes in methylation pattern of DMRs on the <i>GNAS</i> locus without mutation in <i>GNAS</i>	Ca and Vit D		6
10	F	PHP	Dystonia of the lower extremities	Running	6.6	CT and MRI: predominant calcification in BG	—	Ca and Vit D		7
11	F	PHP	Writhing and shaking of both upper limbs	Playing sport	7.5	CT: calcification in BG and frontal lobe white matter	—	Ca and Vit D		8
12	F	AD PHP1B	Forward fall seizures, facial convulsions, and tremor of limbs	—	7.4	MRI: normal	A 3-kb deletion upstream of the <i>GNAS</i> locus on 20q13.3 inherited from the mother	CBZ	Ca and Vit D	9
14	F	AD PHP1B	Paroxysmal kinesigenic dyskinesia	—	5.7	MRI: normal	A 3-kb deletion upstream of the <i>GNAS</i> locus on 20q13.3 inherited from the mother	—	Ca and Vit D	9
15	M	Sporadic PHP1B	Dystonia of the shoulder joint, wrist, knee, and metacarpophalangeal joint	Upper and lower limb extension exercises	7.7	CT and MRI: bilateral calcification in frontal and parietal cortex and thalamus	Methylation abnormalities of the DMR(s) without copy number change on the <i>GNAS</i> locus	CBZ	Ca and Vit D	10

16	M	Sporadic PHP1B	Dystonic movements involving mainly the left hand	Writing and physical exercise	5.5	CT: Multiple subcortical and diffuse BG calcifications	Methylation defects of the <i>A/B</i> DMR without deletion involving <i>STX16</i>	Ca and Vit D	11
17	M	PHP	Dystonia of upper and lower limbs, facial rigidity	Activity	7.7	CT: Calcification in BG, thalamus, cortical arcuate fiber	—	CBZ Ca and Vit D	12
20	F	PHP	Parkinsonism including tremor, rigidity, bradykinesia, stooped posture	—	9.8	CT: normal	—	—	13
25	M	PHP	Dystonia of the neck and extremities	Physical exercise	5.3	CT: Nonspecific findings (no BG calcification)	—	Ca	14
25	M	PHP	Dystonia of the arm, open mouth, general ankylosis	Running and exercise	4.9	MRI: symmetric calcifications on the bilateral putamen and dentate nucleus.	—	Ca and Vit D	15
27	F	PHP	Dystonia of upper and lower limbs	Physical exercise	4.4	CT: bilateral calcification in the BG	—	Ca	14
52	F	AD PHP1A	Parkinsonism including bradykinesia and muscular rigidity	—	7.4	CT: calcification in BG MRI (T1WI and T2WI): increased signal intensity in bilateral caudate nucleus and thalamus	Loss-of-function mutation in <i>GNAS</i> NM_000516.5:c.343C>T (NP_000507.1:p.Pro115Ser)	Ca and Vit D	16
58	F	PHP1	Parkinsonism including immobility, mask-like facies, pill-rolling tremor, cogwheel rigidity	—	4.9	CT: BG calcification	—	Ca and Vit D	17

Dx, diagnosis; AD, autosomal dominant; PHP, pseudohypoparathyroidism; CT, computed tomography; MRI, magnetic resonance imaging; T1WI, T1-weighted image; T2WI, T2-weighted image; BG, basal ganglia; CBZ, carbamazepine; Ca, calcium; Vit D, vitamin D.